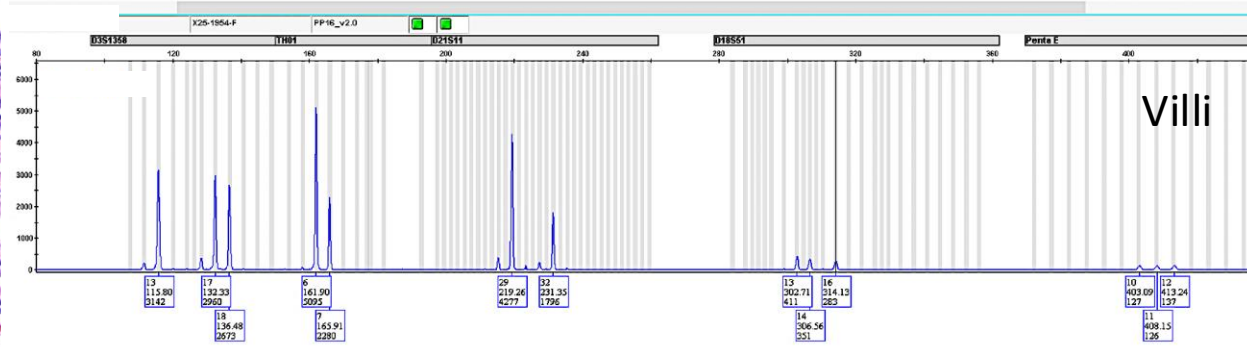
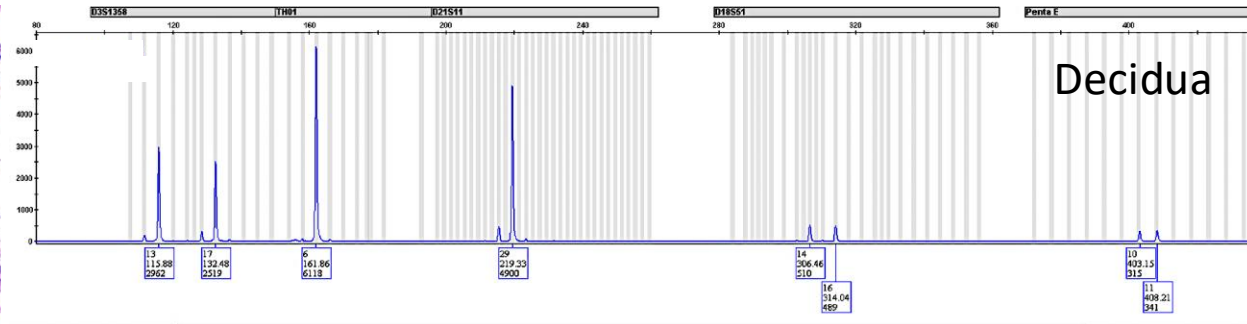
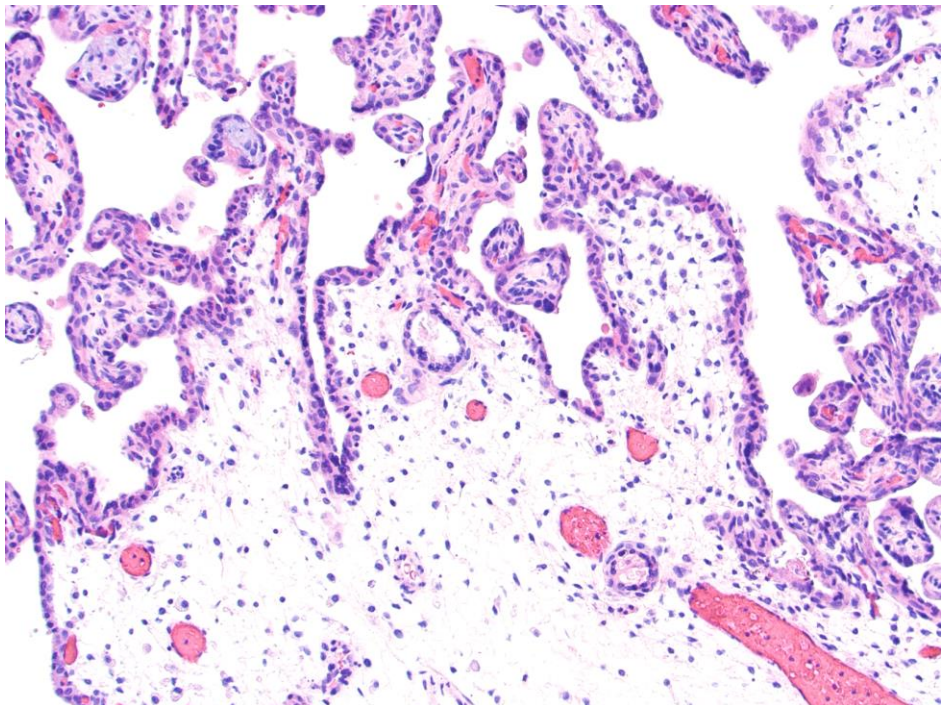
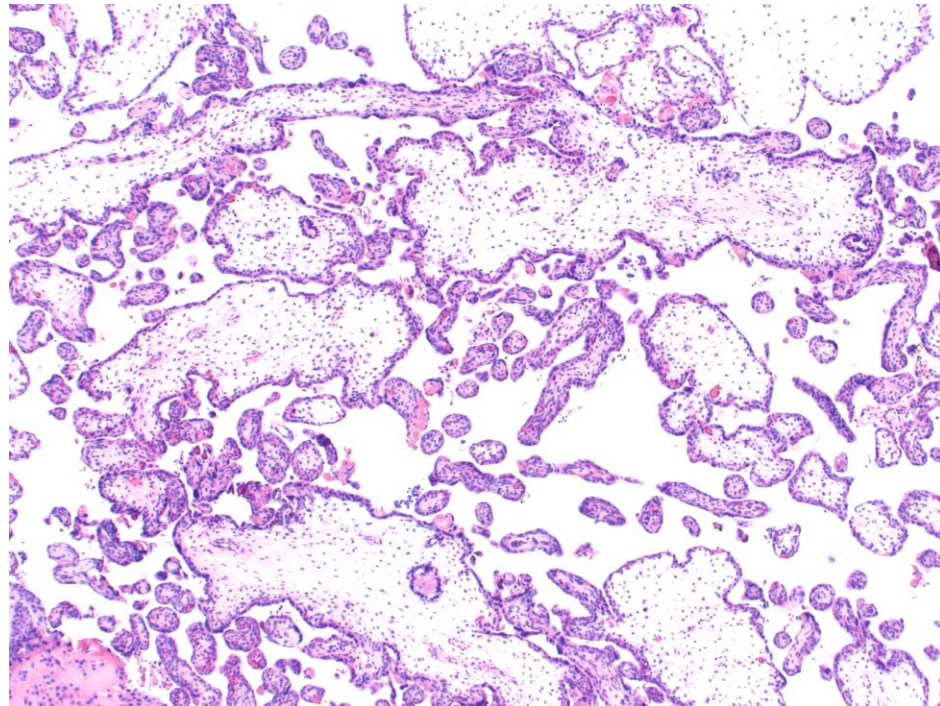
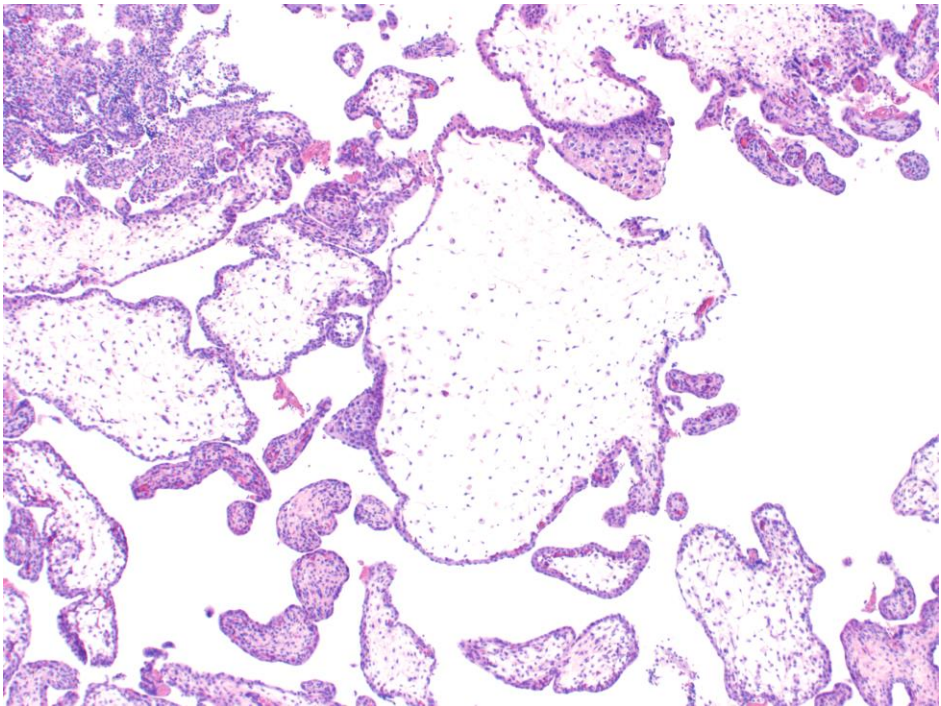




Patient in her 30s presenting with fetal demise at 15 weeks' gestation with multiple fetal anomalies and triploidy by microarray analysis of chorionic villi



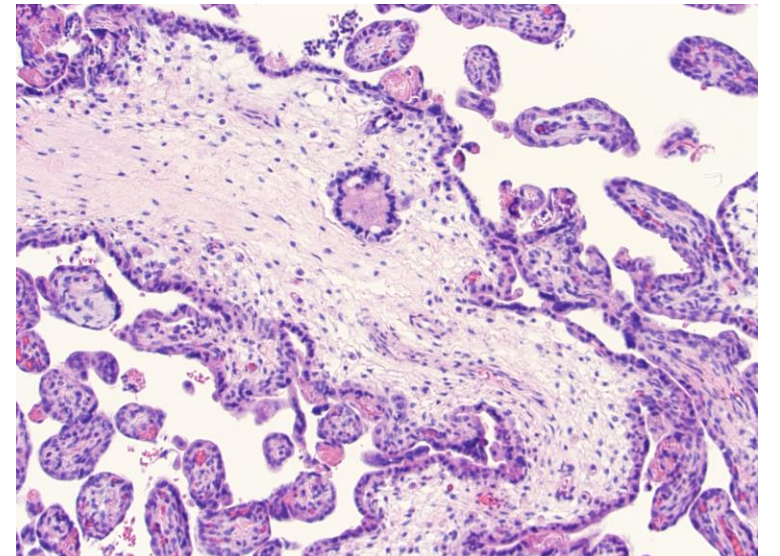
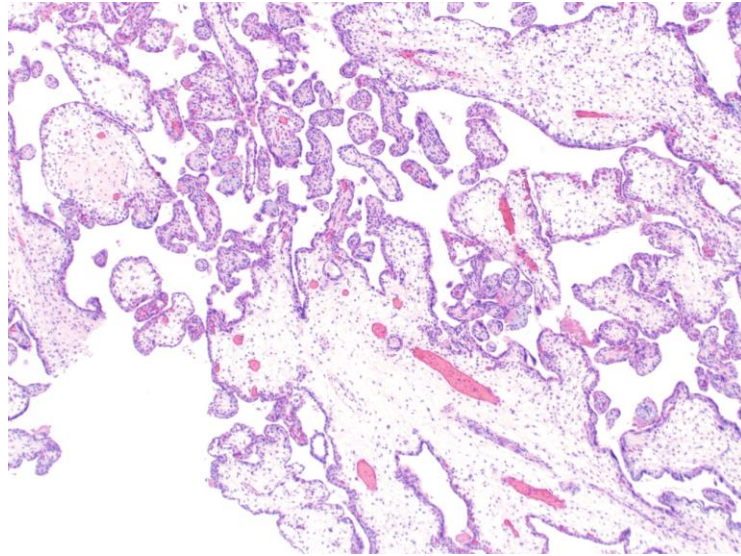
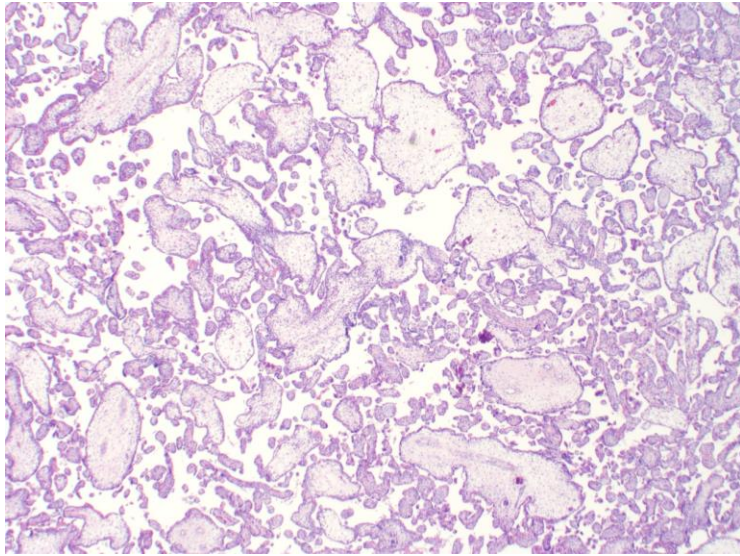
Diagnostic Options

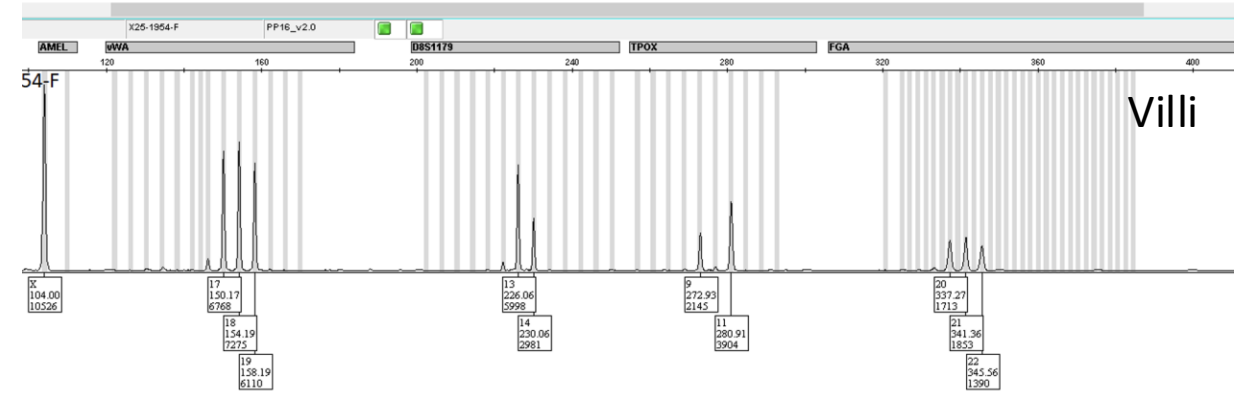


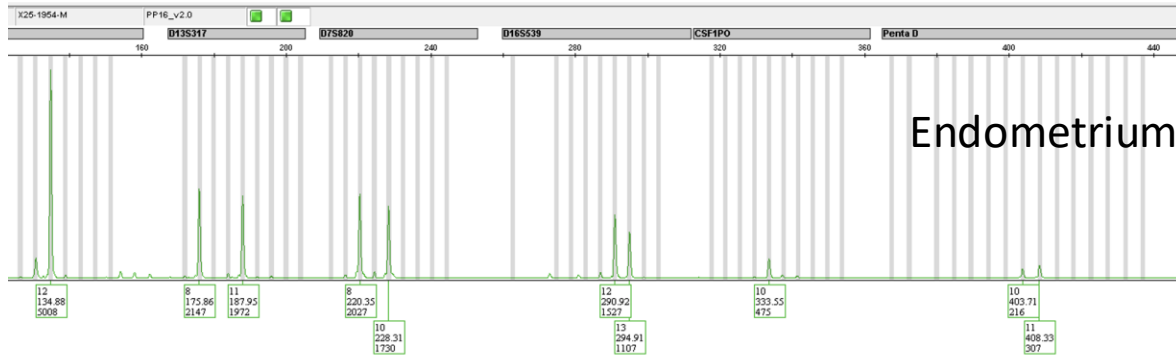
A: Non-molar triploid gestation

B: Dispermic partial mole

C: Monospermic partial mole

Additional Histologic Images





STR Genotyping (full panel): Three allelic copies are present at all informative STR loci in the chorionic villi: each locus harboring two matching maternal alleles and one paternal allele (comparing with the allelic pattern of the gestational endometrium).

Summary:

The chorionic villi show abnormal shapes and sizes with apparent two villous populations, trophoblastic pseudoinclusions and villous edema. The morphological features are suggestive of partial hydatidiform mole.

Although CVS karyotyping identified a triploid gestation, STR genotyping demonstrates the presence of three allelic copies at all STR loci, including two matching maternal alleles and one paternal allele at each STR locus consistent with digynic-monoandric non-molar gestation.

Final Diagnosis:

Digynic Triploid Non-molar Gestation